

# ECG interpretation №879631\*

from 11.02.2022 11:13:27, duration 180 sec.

device Serdechko, cardio-cloud.ru



HEALTHLINE  
innovate life quality

Problems revealed: 0

Dangerous: 0

Important: 0

Age: 64 years

Sex: male

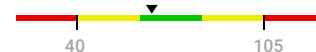Weight: 93 kg

Height: 190 cm

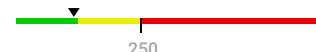Body mass index (BMI): 26

Overweight

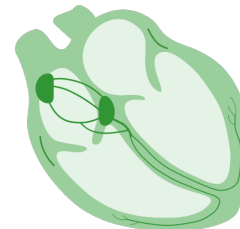
Heart rate 64 bpm



Stress-Index 109



Index of activity of the regulatory systems



For doctor

Electrical axis	
P	122 ms
PR (PQ)	167 ms
QRS	90 ms
QT	389 ms
QTc	402 ms

## Dangerous

Atrial fibrillation

computer check

doctor check

Not revealed

Not revealed

Atrial flutter

Not revealed

Not revealed

Supraventricular tachycardia

Not checked

Not revealed

It is impossible to rule out myocardial infarction

Not checked

Not revealed

## Important

Short PR interval

Not checked

Not revealed

Wolff-Parkinson-White syndrome

Not checked

Not revealed

First-degree atrioventricular block

Not checked

Not revealed

Bundle branch block

Not revealed

Not revealed

Prolongation of the QT interval

Not checked

Not revealed

Second-degree type 1 atrioventricular block

Not checked

Not revealed

Second-degree type 2 atrioventricular block

Not checked

Not revealed

Shortening of the QT interval

Not checked

Not revealed

Sinoatrial block

Not checked

Not revealed

Sinus arrhythmia

Not revealed

Not revealed

Sinus bradycardia

Not revealed

Not revealed

Sinus tachycardia

Not revealed

Not revealed

Premature supraventricular contraction

Not revealed

Not revealed

Third-degree or complete atrioventricular block

Not checked

Not revealed

Premature ventricular contraction

Not revealed

Not revealed

Signs of left ventricular hypertrophy

Not checked

Not revealed

Signs of right ventricular hypertrophy

Not checked

Not revealed

Moderate changes in the myocardium

Not checked

Not revealed

Significant changes in the myocardium

Not checked

Not revealed

It is impossible to rule out myocardium focal changes

Not checked

Not revealed

Signs of benign early repolarisation

Not checked

Not revealed

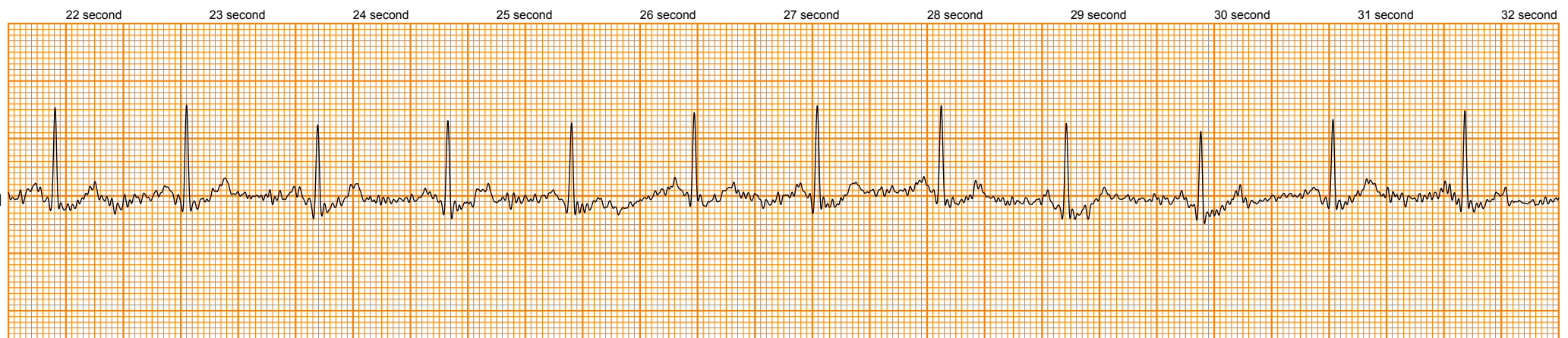
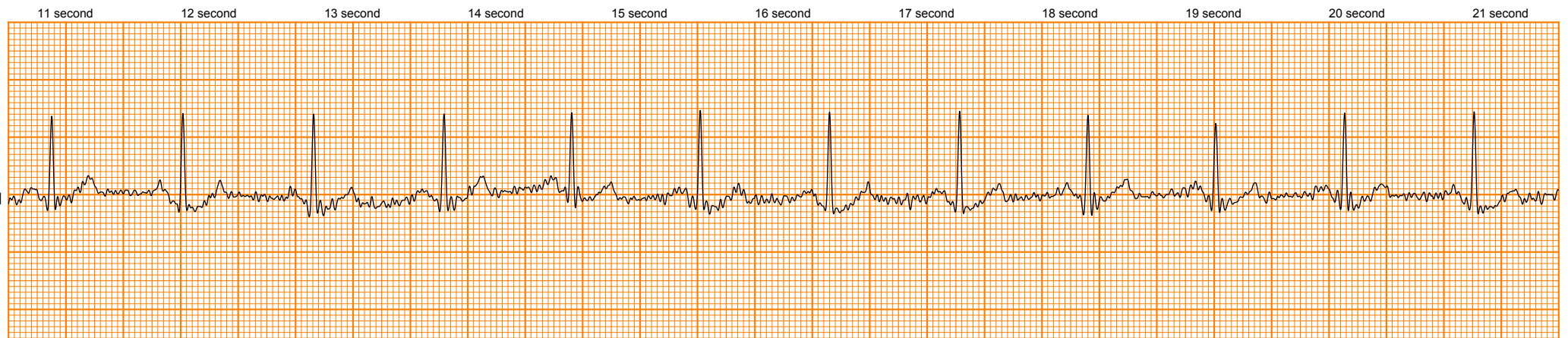
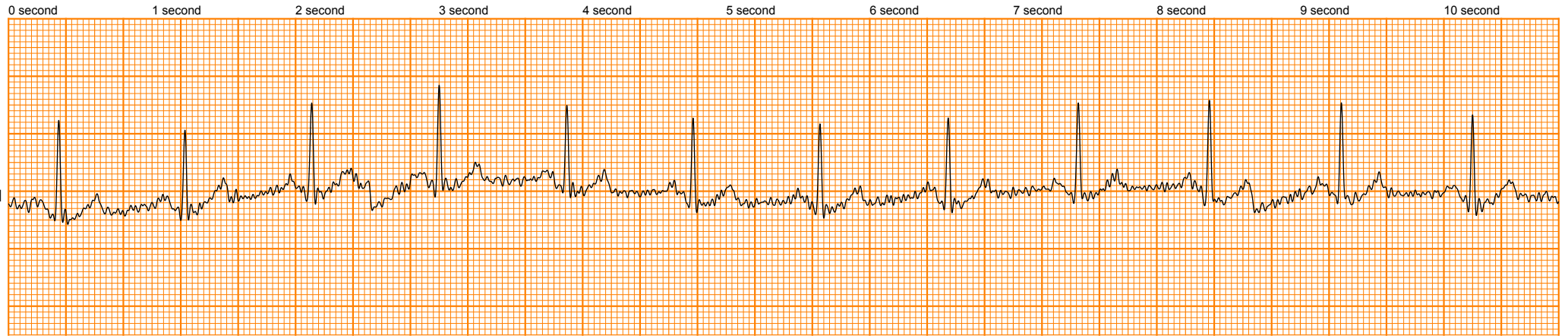## Conclusion of doctor

cardiac arrhythmias and cardiac conduction disturbances are not revealed, it is recommended to repeat the measurement every six months or if you feel unwell

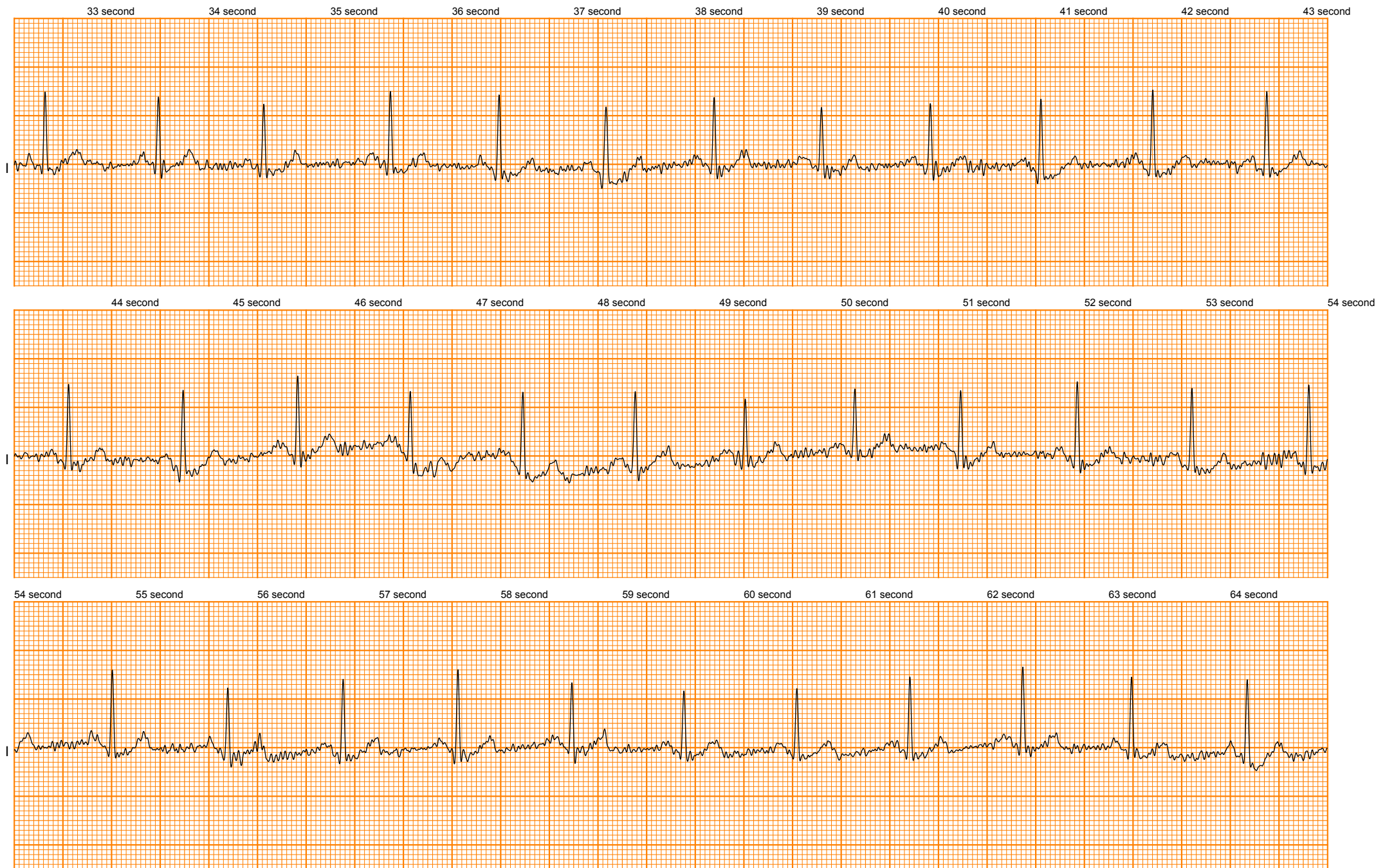
Doctor: Григорьева Елена Сергеевна

Company: ИП Григорьева Е.С.

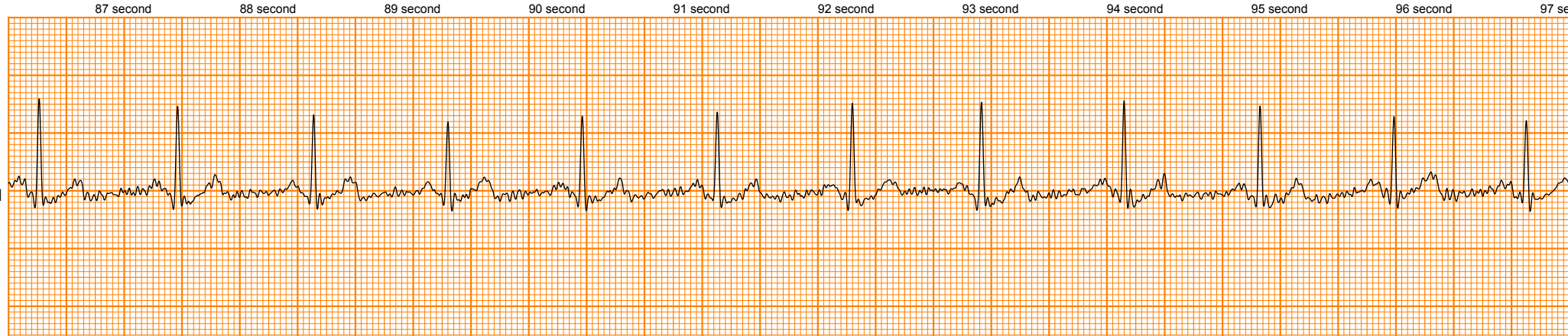
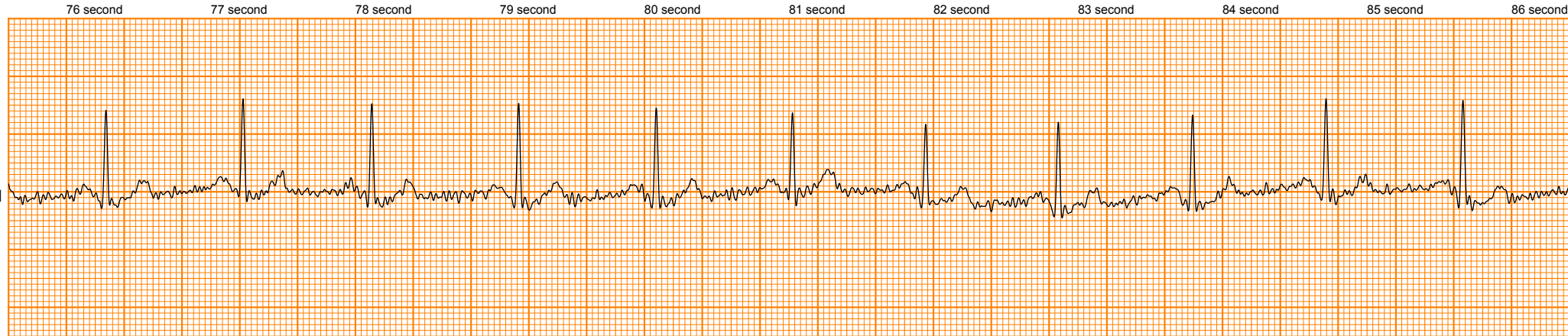
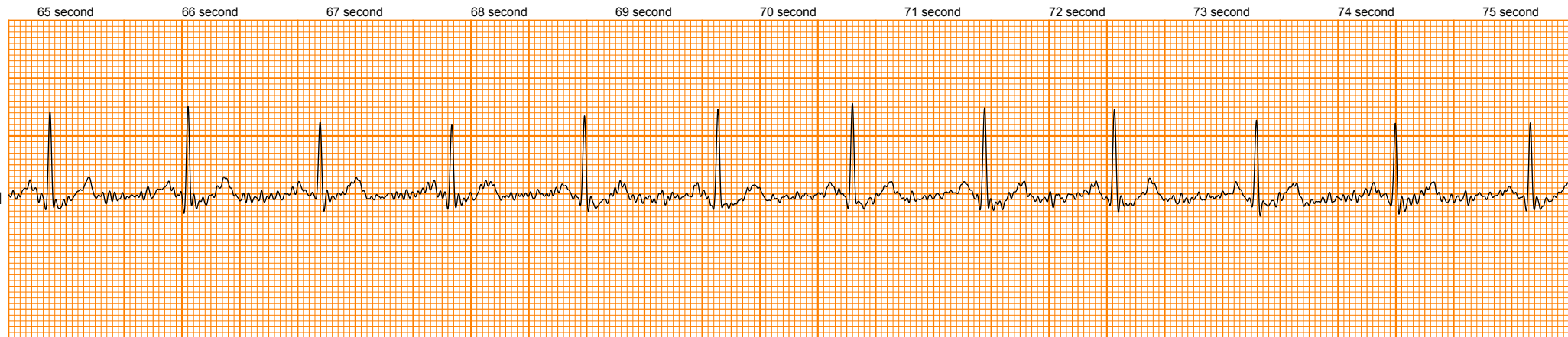




25mm/s 20mm/mV №879631

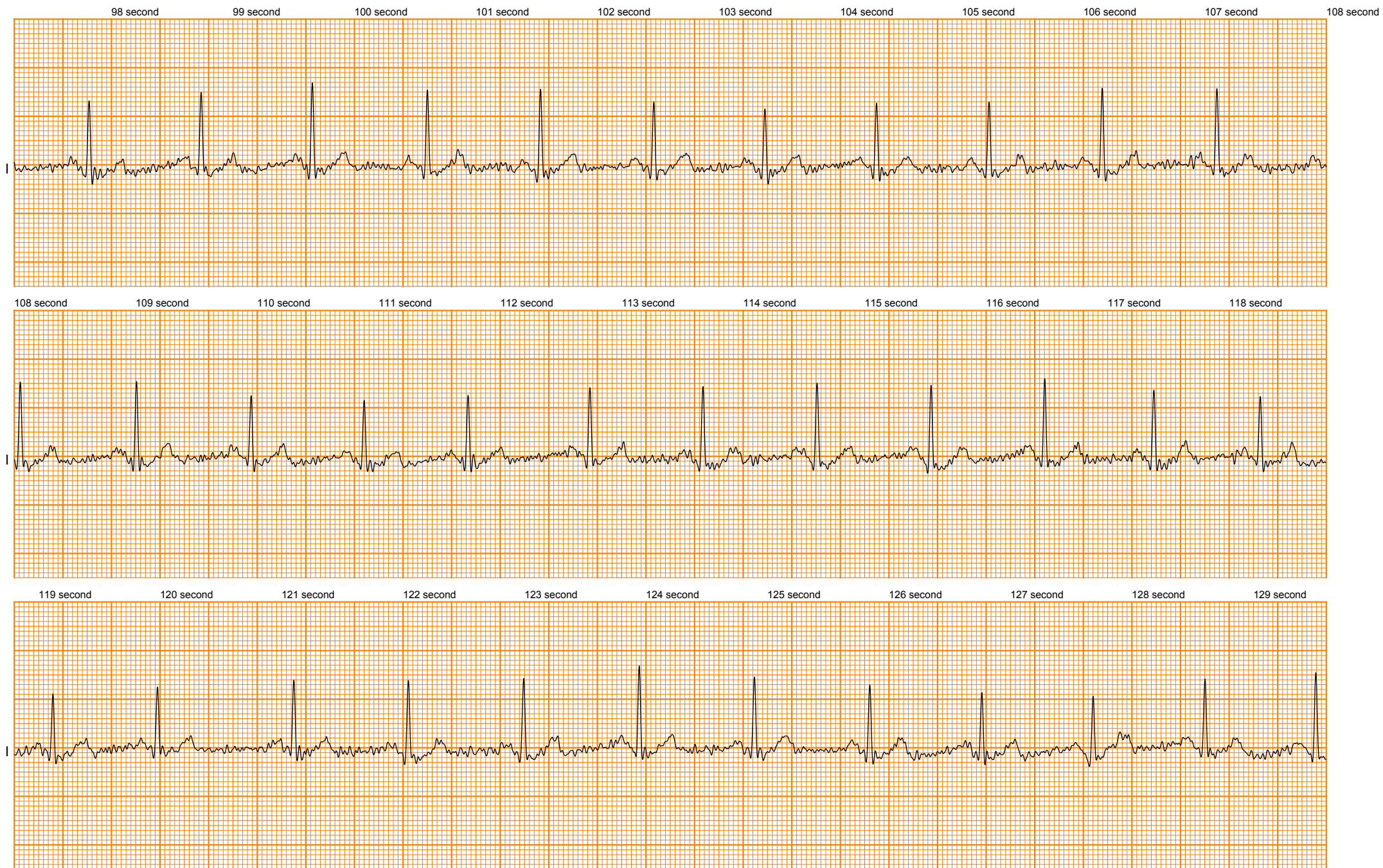


25mm/s 20mm/mV №879631

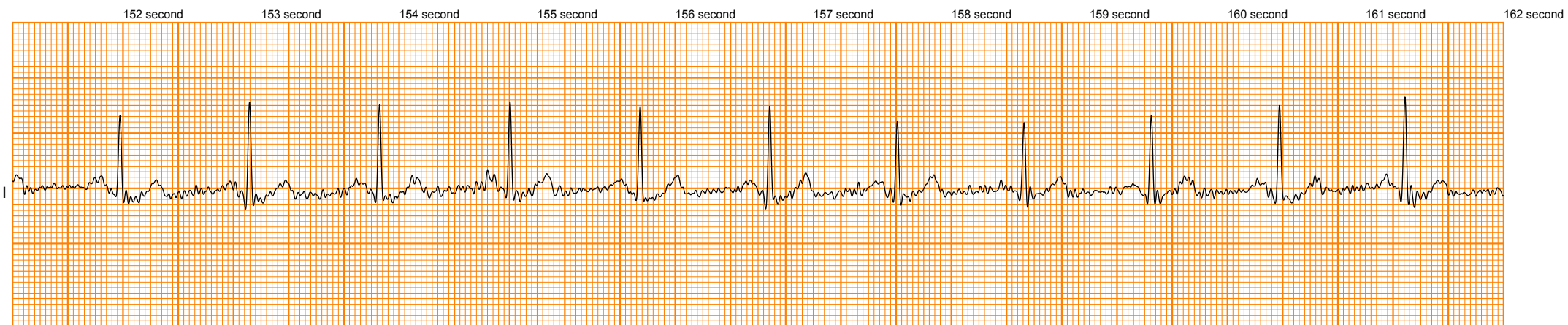
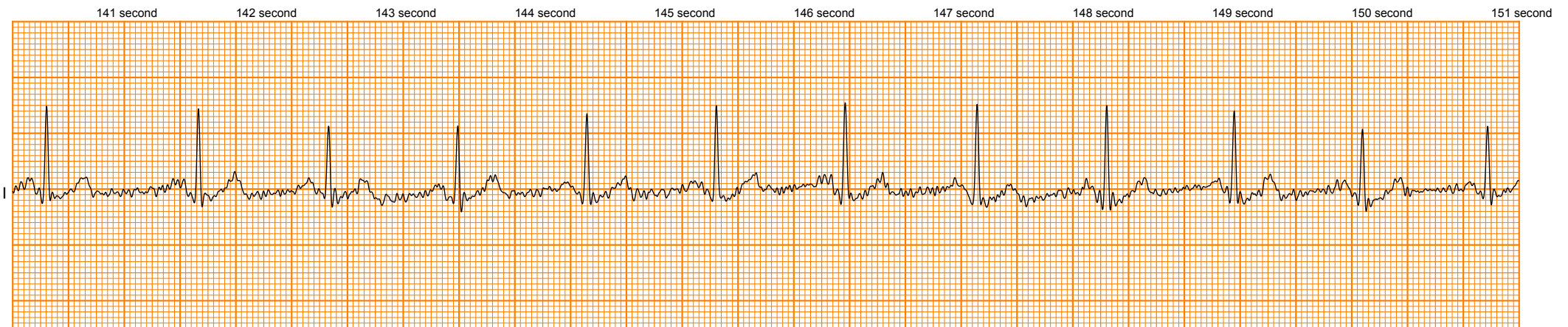
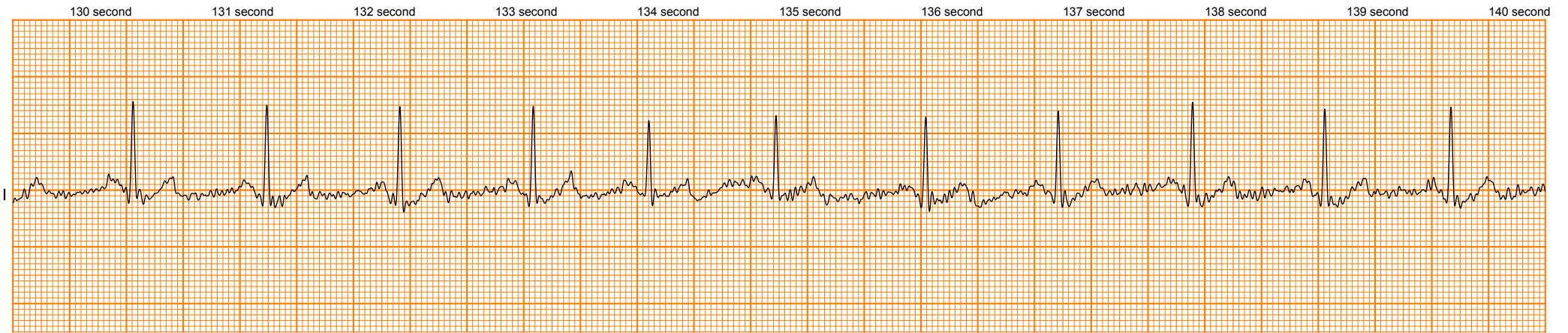


25mm/s 20mm/mV №879631

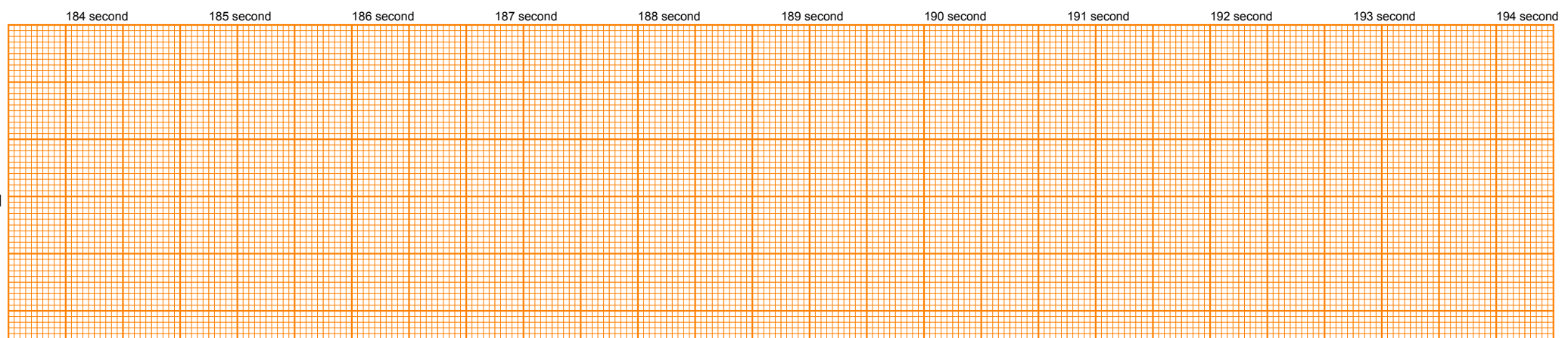
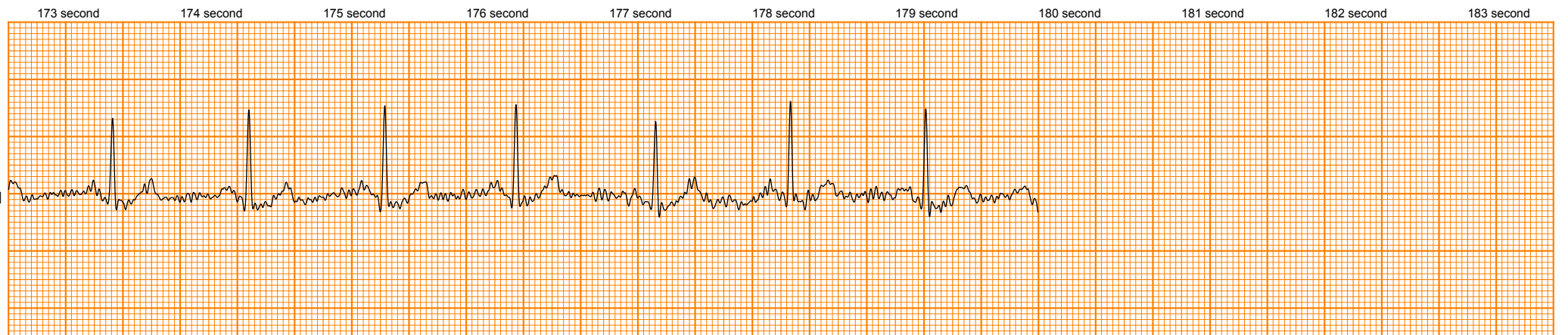
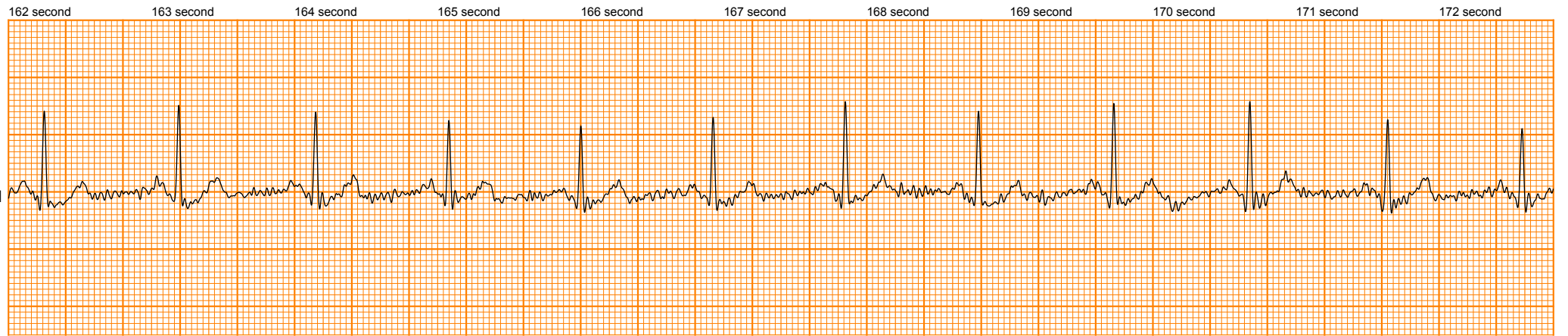




25mm/s 20mm/mV №879631



25mm/s 20mm/mV №879631



25mm/s 20mm/mV №879631